VOL. 5 NO. 1, JUNE 2018

ISSN 2347-1859

DENTAL LAMINA

JOURNAL OF DENTAL SCIENCES

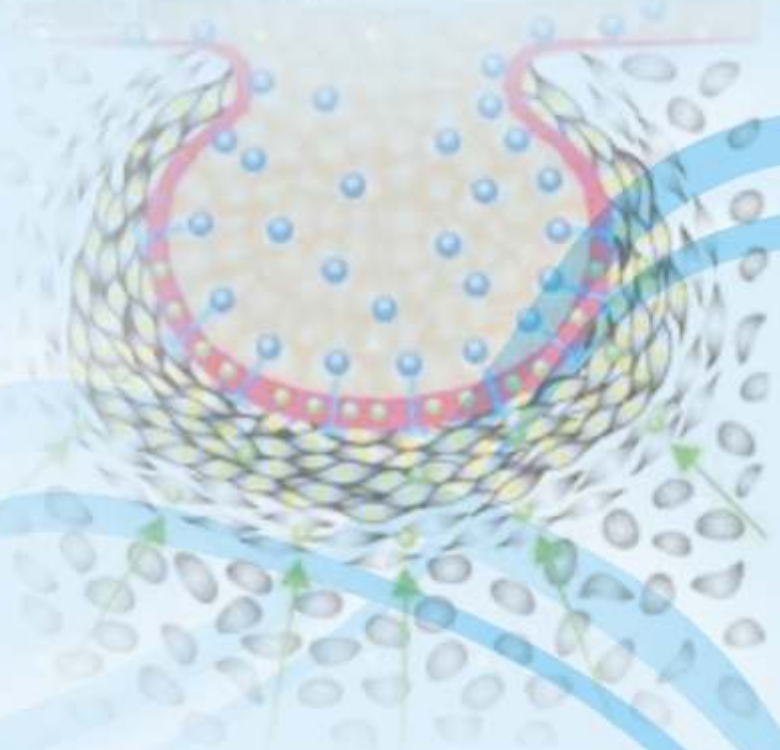

MANAV RACHNA
Vidyanatariksha

"DENTAL LAMINA"
JOURNAL OF DENTAL SCIENCES

Publisher/ Printer

Published at : Plot No. 6, Industrial Area, NIT Faridabad, Haryana
Printed at : Prabhakar Press, Plot No. 6, Industrial Area, NIT Faridabad, Haryana

"DENTAL LAMINA"

JOURNAL OF
DENTAL SCIENCES

VOL. 5 NO. 1 JUNE 2018

ISSN 2347-1859

EDITORIAL

Our sedentary lifestyles have led us to fall prey to deficiency of a vitamin which is associated with a spectrum of development and health maintenance. Vitamin D is responsible for the absorption of calcium and helps in maintaining a good immune response.

Vitamin D deficiency is thought to increase the risk of tooth decay and gum disease. Studies have shown that vitamin D deficiency and dental caries go hand in hand. A study published by the American Academy of Pediatrics inferred that an appropriate level of vitamin D in expectant mothers was associated with less chances of developing Early Childhood Caries.

We as dentists might be the first ones to detect a deficiency of this sunshine vitamin. Anthropologists Lori D 'Ortenzio and Megan Brickley discovered that vitamin D deficiency leads to deformities in dentin which can be viewed on a dental X Ray. The deficiency of this vitamin causes an alteration in the shape of the pulp horns which may appear constricted and asymmetrical and the arch between them seems to be lost. A dentist on seeing this deformity can recommend a blood test to determine the blood levels of this vitamin.

The anti inflammatory property of vitamin D is shown to reduce gingivitis. Thus an appropriate blood level is needed for good health of our gingival tissues. the optimal blood level of vitamin D is 40-60 ng/ml.

Maintaining an appropriate level of vitamin D in our blood plays an important role in preventing dental diseases. Our lifestyles need a change. We need to spend time in outdoor activities to absorb this super vitamin.

Dr. Shveta Sood
Editor In Chief

INDEX

A) LETTER TO EDITOR

B) REVIEW

C) CASE REPORT

NEED FOR ENTREPRENEURSHIP EDUCATION IN UNDERGRADUATE DENTAL CURRICULUM

Dr. Ankur Sharma*, Dr. Meena Jain, Dr. Nisha Yadav***, Dr. Puneet Chahar*****

* Lecturer, Department of Public Health Dentistry, Manav Rachna Dental College, Faridabad
** Reader and In-charge, Department of Public Health Dentistry, Manav Rachna Dental College, Faridabad
*** Senior Lecturer, Department of Public Health Dentistry, Manav Rachna Dental College, Faridabad

Dear Editor,

We read the article titled 'Significance and Relevance of Orientation Program for First Year Students in Dental Colleges - A Report'[1] in the current volume of Dental Lamina with interest. We appreciate the importance of orientation programs and adoption of such progressive methods of making undergraduate dental education a more fruitful endeavor. Such programs make undergraduate dental courses easier and less stressful. Through the present letter, we aim at emphasizing the need for another addition to improvement of undergraduate dental curriculum in form of Entrepreneurship education.

Entrepreneurship in form of innovation directed at business development is seen as one of the major areas of sustainability for higher education in the future[2]. As more and more dental students graduate each year, the need for entrepreneurship and self-reliability is bound to increase[3]. Moreover, dental graduates are more likely to start-up their own practice and invest into their own enterprise as compared to other professionals like surgeons, nurses, and engineers etc., who are more likely to be absorbed in an employment. Hence a need of a competitive entrepreneurial ecosystem in dental colleges seems to have become a necessity rather than an option. With this view many universities internationally have recognized the needs of dental professionals as entrepreneurs and have started dual degrees imparting dental as well as management education to the students[4]. However, such options are unavailable to the undergraduate dental students in India.

Further, innovation has been identified as the spearhead of growth of dental industry as well as dental practice in the future. Both innovation, as well as dissemination of innovation is important for future growth of dentistry into a more client friendly and person centered profession. Such innovation should include both technological improvement and process improvement. As dental students are set to become the key part of dental care provision, they are at a strategic position where they may look at the problems by both patient as well as a clinician's perspective. Therefore, encouraging and engaging students into product as well as process innovation, and dissemination of innovation would be critical to the future growth of dental profession as a whole[5].

Entrepreneurship development in dental students may also help in improving the quality of learning. Dental education has been acknowledged as a highly stressful coursework[6,7,8], with stress and anxiety as major issues that affect learning. Entrepreneurial development is known to be associated with higher Emotional Intelligence (EI) among students and subsequently, capability to cope with stressful situations[9]. Entrepreneurship education may also help to alleviate future anxiety in students as it is associated with increase in self-efficacy and ability to take decisions. Therefore, entrepreneurship education would be helpful in improving the quality of overall education imparted in dental schools.

Various dental schools in the developing world are accepting the need of entrepreneurship education, innovation and start-ups involving dental educational institutions. A recent paper outlines the need of university-industry interactions and setting-up of dental Science and Technology Parks (STPs) in line of systems like Stanford University Science Park (Silicon Valley) for fostering innovation[10], scientific development and entrepreneurship in dentistry. However, the beginnings for developing countries like India need to be humble and take their own course towards future. Such beginnings are more likely to occur in the dental institutes that are located in multidisciplinary campuses where an innovation ecosystem is already in place and needs to be extended to dental sciences. Such an ecosystem would provide the

necessary infrastructure and platform for entrepreneurial development of dental students. Further, it would also promote research and innovation among the faculty members so that they may guide and mentor the students towards entrepreneurial development.

Certain institutes in India have taken leadership position in providing such platforms for students. Government sector institutes of post-graduate dental learning have provided some such platforms for students. The authors' institution has been instrumental in providing its students various platform for entrepreneurial development. Idea pitching events where dental students are encouraged to participate with students of other streams have been conducted in the past. Mentorship has been given to students through which they have been able to obtain governmental grants in order to develop their innovative ideas. However, an extensive coverage of entrepreneurial development education formal courses like optional dual-degree courses, or short term courses in entrepreneurship are still missing from Indian dental education scenario.

Introduction of short term entrepreneurial courses as optional learning programs or dual degree programs would go a long way in future development of dental education and dental profession. Important stakeholders and regulatory bodies like the dental council should consider recommendation of such programs and courses into dentistry for a better professional development of dental students in the future. Considering the extensive spread of dental education in India, these programs may make India a future dental innovation and entrepreneurship hub.

References

1. Goyal A, Singh A, Aggrawal A, Doomra R, Jain A, Jain A. Significance and relevance of orientation program for first year dental students in dental colleges - A report. Dental Lamina Journal of Dental Sciences. 2017 Dec;4(2):4-9.
2. Provasnek AK, Schmid E, Geissler B, Steiner G. Sustainable corporate entrepreneurship: performance and strategies toward innovation. Business Strategy and the Environment. 2017 May 1;26(4):521-35.
3. Palaskar JN. Entrepreneurship in dentistry. Journal of Dental and Allied Sciences. 2014 Jul 1;3(2):69.
4. Remington TF. Business-government cooperation in VET: a Russian experiment with dual education. Post-Soviet Affairs. 2017 Jul 4;33(4):313-33.
5. Agarwal A, Anderson J, Sarfaty S, Hirsch AE. The value of an elective in business and leadership for medical students. The Journal of medical practice management: MPM. 2015;30(4):276.
6. Elani HW, Allison PJ, Kumar RA, Mancini L, Lambrou A, Bedos C. A systematic review of stress in dental students. Journal of dental education. 2014 Feb 1;78(2):226-42.
7. Jain M, Sharma A, Singh S, Jain V, Miglani S. The stress of clinical dental training: A cross-sectional survey among dental students and dentists of a dental college in India. Journal of Indian Association of Public Health Dentistry. 2016 Oct 1;14(4):434.
8. Yadav NR, Jain M, Sharma A. Stress - A silent killer in dentistry. Dental Lamina - Journal of Dental Sciences. 2017 Dec;4(2):35-40.
9. Kolahi J. Dental science and technology parks: Rethinking university-industry connections. Dental Hypotheses. 2015 Apr 1;6(2):40.
10. Karimi S, Biemans HJ, Lans T, Chizari M, Mulder M. The Impact of entrepreneurship education: A study of Iranian students' entrepreneurial intentions and opportunity identification. Journal of Small Business Management. 2016 Jan 1;54(1):187-209.

YES! DENTISTS DESERVE A STRESS FREE LIFE

Abstract

Stress has entered everyone's life nowadays. A dentist is vulnerable to physical as well as mental stress, thus resulting in hampered productivity and satisfaction. Age old techniques like yoga, meditation, pranayama etc. are known to provide relief from various kinds of stress. So, making these techniques a part of life may enhance the quality of life.

Dr. Karishma Chhabra* , Dr. Hind Pal Bhatia **, Dr. Shveta Sood*, Dr. Naresh Sharma****, Dr. Akshara Singh*****

* 2nd Year Post Graduate Student, Department of Pedodontics and Preventive Dentistry, Manav Rachna Dental College, Faridabad
** Professor & Head, Department of Pedodontics and Preventive Dentistry, Manav Rachna Dental College, Faridabad
*** Professor, Department of Pedodontics and Preventive Dentistry, Manav Rachna Dental College, Faridabad
****Reader, Department of Pedodontics and Preventive Dentistry, Manav Rachna Dental College, Faridabad
*****Senior Lecturer, Department of Pedodontics and Preventive Dentistry, Manav Rachna Dental College, Faridabad

Introduction

A healthy and happy life is fundamental right of every human-being and stress seems to be the biggest obstacle to it. The stress may be of many kinds in a dentist's life—Physical, Mental, Emotional Stress in the form of fatigue, tension, dizziness, sleeplessness, tachycardia, gastrointestinal symptoms, irritability, anxiety, and cynicism degrades the quality of life and therefore, the quality of dental practice. Meditation, yoga and chanting have transformed many lives, thus, giving hope for all the stressful dentists.

Physiology of stress in a Dentist's life

Hans Selye (1946) coined the term stress and postulated the possible mechanism of activation of the adrenocortico-pituitary axis. The stress-induced responses either result in change in behavior or are transmitted to the hypothalamic–pituitary–adrenal (HPA) axis to release corticotrophic releasing hormone (CRH) from the hypothalamus. CRH activates the pituitary gland to release adrenocorticotropic hormone (ACTH), which in turn induces the release of glucocorticosteroids like cortisol from the adrenal cortex.[1]

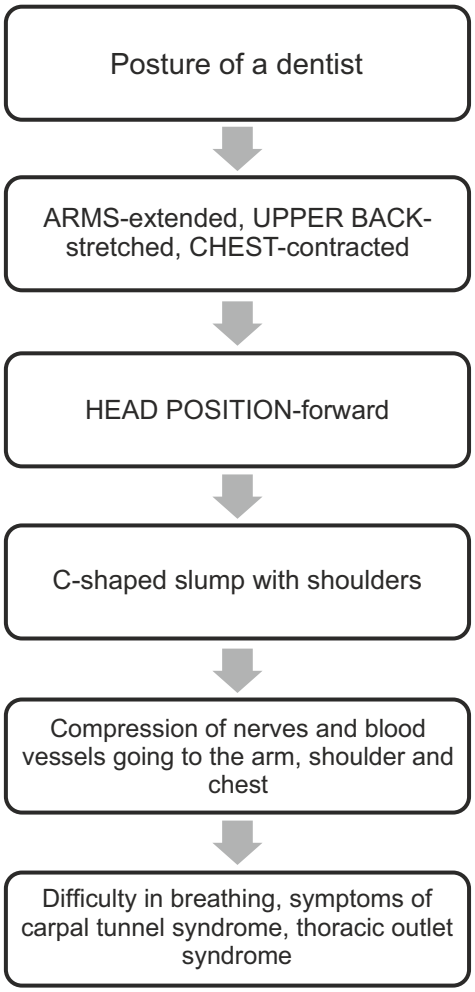

Solution for the problem

John Lennon has rightly said, "There are no problems, only solutions"

For this long term problem called stress, we need a tried, tested & reliable solution which can help all of us physically healthy, mentally alert & emotionally positive. This will help to create a positive environment at the clinic, making our practice more productive & patients more satisfied, while being totally relaxed physically, mentally and emotionally. Spiritual practices like yoga, meditation, chanting etc. can definitely make the stress disappear from our life.

Meditation

Meditation is the way to take deep rest and be alert & conscious at the same time! It is the skill to calm the mind and get in touch with your inner joy. Meditation is the journey from movement to stillness, from sound to silence.

The reported benefits of mindfulness training are numerous. Empirical findings suggest that mindfulness training can be applied for a broad range of life difficulties, ranging from the treatment of depression (Broderick, 2005) and somatic complaint. It is known that in healthy aging too, the elderly obtain a 1-2% loss in hippocampus volume annually. In contrast, after 6 months of yoga intervention, the hippocampus gained volume.[2]

Long term meditators have higher gray matter density in lower brain stem regions cardiorespiratory parasympathetic effects and traits, as well as the cognitive, emotional, and immunoreactive impact.[3]

Breathing Techniques & Yoga

Yoga and Breathing techniques are recommended for relaxation, stress management, control of psychophysiological states, and to improve organ function. Yogic breathing, defined as manipulation of breath movement, has shown to positively influence immune system imbalances, and pscychological or stress-related disorders.

Yogic breathing, pranayama is a unique method for balancing the autonomic nervous system and influencing psychological and stress relate disorders. One specific form of exercises is SKY[4] (Sudarshan Kriya Yoga) which is shown to have favourable effects on mind-body system.

SKY consists of a specific sequence of varying breathing rates separated by brief perios of normal breathing. These breaths influence fibres of vagus nerve, which in turn induces physiological changes in organs, glands, and ascending fibres to thalamic generators, the limbic system, and cortical areas. This may account for rapidity and diversity of SKY effects like experience of calmness and relaxation, combined with increased vigilance and attention.

Majority of the dentists experienced pain in the neck and lower back regions. A recent study showed that The prevalence of musculoskeletal pain in dentists practicing yoga is 10.5%, and it is 21.7% in those dentists practicing some sort of physical activity. The prevalence of musculoskeletal pain in dentists without any regular physical activity is 45.6%.[5]

Chanting

Scientific studies on 'Om" suggest that the mental repetition of "Om" results in physiologiacal alertness, increased sensitivity as well as synchronicity of certain biorhythms, and increased sensitivity to sensory transmission.

The autonomic and respiratory variables were studied in seven experienced Om meditators (with the experience ranging from 5 to 20 years). Each subject was studied in two types of sessions–meditation (with a period of mental chanting of Om) and control (with a period of nontargeted thinking). The meditators showed a statistically significant reduction in the heart rate during meditation compared to the control period. During both types of sessions, there was a comparable increase in the cutaneous peripheral vascular resistance. This was interpreted as a sign of increased mental alertness even while being physiologically relaxed[6]

Conclusion

The ancient practices are precious gifts to us. All the miseries of the modern life can be replaced by calmness, stability and clarity in mind. Medical science is rediscovering and validating many of the ancient health practices from traditional cultures worldwide. The practices of meditation, breathing techniques and yoga are cost-effective, well-tolerated tools that can be easily integrated into diverse community care models.

Stretches for relief from wrist pain and wrist strengthening

Yoga poses for relief from pain neck, shoulder and back

Paschim Namaskarana

Lengthening the spine

Bending the spine forward and backward

Twisting the spine to right and left

Stretching spine from side-to -side

Majriasana or cat sretch

Ustrasana or camel pose

Pavan muktasana

Trikonasana or triangle pose

Natrajasana

Savasana or corpse posture

References

1. Katuri KK, Dasari AB, Kurapati S, Vinnakota NR, Bollepalli AC, Dhulipalla R. Association of yoga practice and serum cortisol levels in chronic periodontitis patients with stress-related anxiety and depression. J Int Soc Prevent Communit Dent 2016;6:7-14.

2. Schreiner I, Malcolm JP. The Benefits of Mindfulness Meditation: Changes in Emotional States of Depression, Anxiety, and Stress. https"//doi.org/10.1375/bech.25.3.156

3. Vestergaard et al. Long-term meditation is associated with increased gray matter density in the brain stem. Neuroreport.2009. 20(2):170-4.

4. Zope S, Zope RA. Sudarshan Kriy Yoga: Breathing for health. International Journal of Yoga.2013. 6(1):4-10.

5. Koneru S, Tanikonda R. Role of yoga and physical activity in work-related musculoskeletal disorders among dentists. J Int Soc Prevent Communit Dent 2015;5:199-204

6. Kumar S, Nagendra H, Manjunath N, Naveen K, Telles S. Mediation on OM: Relevance from ancient texts and contemporary science. Int J Yoga 2010;3:2-5.

7. Koneru S, Tanikonda R. Role of yoga and physical activity in work-related musculoskeletal disorders among dentists. J Int Soc Prevent Communit Dent 2015; 5:199-204.

8. Nayak NN, Shankar K. Yoga: A therapeutic approach. Phys Med Rehabil Clin N Am 2004; 15:783-98.

9. Pollack R. Dental office ergonomics: How to reduce stress factors and increase efficiency. J Can Dent Assoc 1996; 62:508-10.

10. Sharma P, Golchha V. Awareness among Indian dentist regarding the role of physical activity in prevention of work related musculoskeletal disorders. Indian J Dent Res 2011; 22:381-4.

11. Brown RP, Gerbarg PL. Sudarshan kriya yogic breathing in the treatment of stress, anxiety, and depression: Part II-clinical applications and guidelines. J Altern Complement Med 2005;11:711-7.

12. Fokkema DS. The psychobiology of strained breathing and its cardiovascular implications: A functional system review. Psychophysiology 1999;36:164-75.

13. Sharma H, Sen S, Singh A, Bhardwaj NK, Kochupillai V, Singh N. Sudarshan Kriya practitioners exhibit better antioxidant status and lower blood lactate levels. Biol Psychol 2003;63:281-91

14. Nayak NN, Shankar K. Yoga: A therapeutic approach. Phys Med Rehabil Clin N Am 2004; 15:783-98.

15. Sovik R. The science of breathing - the yogic view. Prog Brain Res 2000;122:491-505

16. Roldan E, Dostalek C. EEG patterns suggestive of shifted levels of excitation effected by hathayogic exercises. Act Nerv Super (Praha) 1985;27:81-8.

ARTICULATORS IN FIXED PROSTHODONTICS- A REVIEW

Abstract

Articulators are surrounded by an aura of mystery. There has been and is still much criticism from dentist, who never teamed the advantages of using such a gnathological tool. Articulators vary from simple devices capable of limited movement to the more complicated types designed to duplicate positional relations of the jaws. This review aims to summarize uses of different types of articulators in fixed prosthodontics

Jigyasa Garg*, Pankaj Dhawan, Pankaj Madhukar***, Piyush Tandan***, Shivam Tomar****, Divyesh Mehta****, Mansi Nautiyal******

* PG student, Dept. of Prosthodontics, Manav Rachna Dental College, Faridabad
** Professor & Head of Department, Dept. of Prosthodontics, Manav Rachna Dental College, Faridabad
*** Professor, Dept. of Prosthodontics, Manav Rachna Dental College, Faridabad
**** Senior lecturer, Dept. of Prosthodontics, Manav Rachna Dental College, Faridabad

Introduction

The search for recording and reproducing jaw movements of individual patient has occupied the mind of dentists for more than a century in different fields of dental sciences. The lower jaw bone (mandible) is capable of rotation about axis in three planes. So, the occlusal morphology of any fixed prosthesis must accommodate free passage of opposing tooth without interfering the movements of mandible. Long–term successful prosthesis, particularly that of crown and bridges work is dependent on proper management of the occlusion, the maintenance of occlusal harmony, and avoiding the creation of occlusal interferences.1 Occlusal interferences must not be incorporated into prosthesis because of their potential of producing temporomandibular disorders. To prevent this problem, articulators are being used in prosthetic dentistry for over several years. Articulators are mechanical instruments that represent the maxilla, mandible and TMJs. Their main task is to provide a frame where it is possible to relate, in the three planes of space, the maxillary cast with the mandibular cast relative to the hinge axis of the patient and of the instrument.2 Casts should be properly mounted in musculoskeletally stable position to evaluate full range of border movements. If casts are mounted in maximum intercuspal position (MIP), then movement of mandible posterior to MIP can not be achieved on articulator. Articulators also proved to be a useful aid in diagnosis and treatment planning as well. Properly mounted casts on articulators provide lingual visualization of occlusal conditions especially in second molar region where soft tissues of cheek and tongue often prevent good visibility.

Selection of an articulator

Articulator may simulate some or all of the mandibular movements depending upon the type of articulator being used. Non adjustable articulators with fixed condylar angle at 30° produces acceptable results for single restorations. There is no provision for adjustment of condylar side shift.[3,4] The only accurate and reproducible position that can be used in non adjustable articulator (fig 1) is one specific occlusal contact position. As this articulator provide movement only in horizontal plane, additional time has to spend by the dentist in patient's mouth in appropriate eccentric movement.

Multiple restorations or FPDs can be fabricated on semi adjustable articulators. Semi adjustable articulators (fig 2) allow for adjustment of condylar inclination and Bennett angle. Intercondylar width is usually fixed at 110mm, but some allow for different intercondylar widths as in that of Whipmix articulator. Condylar angle and Bennett angle are obtained from individual protrusive and lateral static occlusal records. Condylar inclination can have a great effect on fossa depth and cusp height of posterior teeth. Facebow transfer decreases tooth hinge axis errors thus vertical dimensions can be altered precisely.[5] Incisal guidance (the anterior guiding component of articulation) is adjusted according to overjet and overbite of the patient.[6] Custom made incisal guidance may be set from an existing incisal scheme(Hanau wide vue II), which mimics the movement of lower incisors over the cingulum of upper incisors when mandible moves from centric relation to protrusive position.[7]

Fig. 1: Mean value articulator(non adjustable)

Fig. 2. Hanau183-2 semi adjustable articulator

Facebow is an instrument used to record the spatial relationship of the maxillary arch to some anatomic reference point or points and then transfer this relationship to an articulator. If the hinge axis is not kinematically located (arbitrary), the interocclusal record must be made at the correct vertical dimension of occlusion. A small hinge articulator has a shorter radius of movement (fig. 3) when closing in centric position. A tooth will travel a steeper arc of closure on a small articulator than in the mouth. A slight positive error occurs on the mesial incline of maxillary teeth and the distal incline of mandibular teeth on casts mounted on a small articulator and no increase in VDO.[8] If the intercondylar distance of the articulator is greater than the mandible, the paths of movement will be distal to the ones in the mouth. If the condylar inclination on the articulator is set at a steeper angle than the patient, the restoration will have a positive error on the protrusive or nonworking side.[9] A negative error occurs when the angle is less steep than the patient and will give greater clearance in excursive movements. A negative error is acceptable as long as centric occlusal contacts are maintained.

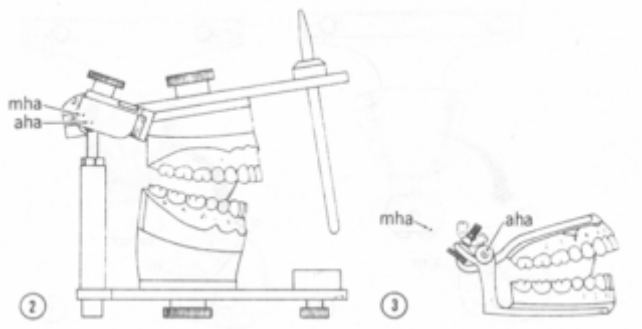

Fig. 3. As a result of the discrepancy between the hinge axis of this semiadjustable articulator (aha) and the mandibular hinge axis (mha), there is a slight discrepancy between the arc of closure of the articulator (broken line) and the arc of closure of the mandible (solid line).

Fig. 3. The large discrepancy between the hinge axis of the small hinge articulator (aha) and the mandibular hinge axis (mha) produces a larger discrepancy between the arc of closure of the articulator (broken line) and the arc of closure of the mandible (solid line).

Fully adjustable articulators are preferred, when extensive treatments are planned in which opposing quadrants are involved or in the reconstruction of entire occlusion.[10] Significant side shift movement and restoring of lost vertical dimensions are possible with fully adjustable articulators.

They believe to allow closer reproduction of condylar movements and also allow curved condylar translation paths. Condylar settings can be transferred by pantographic or stereographic tracings. Hinge axis locator is used to locate the true axis of the patient. Intercondylar distance is set at precise millimeter distance as determined by the patient. It aids in development of restoration that is in close harmony with eccentric pathway of centric cusps.

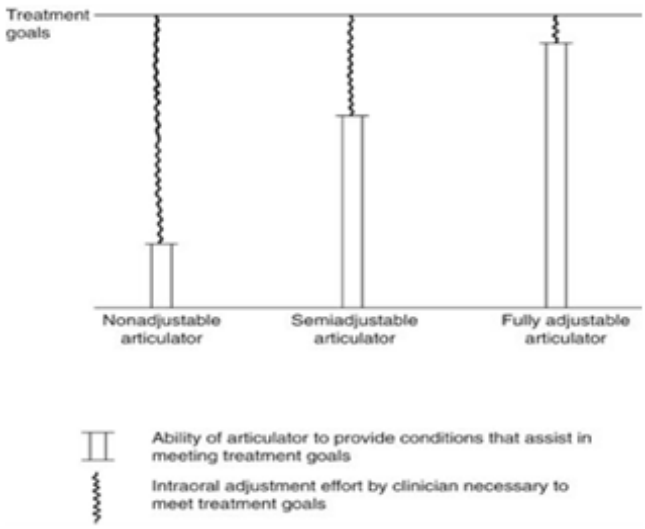

Fig. 4. Contribution of each type of articulator in reaching the treatment goals.

Virtual articulators are used nowadays in CAD/CAM production of indirect dental prosthesis and has been used to study mandibular movements. They are intended to use as tool for analysis of complex static and dynamic occlusal relations. These articulators require 3D representation of jaws as input data. Plaster models of upper and lower jaws are scanned to obtain and digitized set of data. Type of articulator is selected depending on the requirement.[11] An animation of jaw movement is generated in order to obtain interfering occlusion points. Finally dental prosthesis is milled and tested in patient's mouth. Prosthesis can be delivered on the same day. They provide many advantages over mechanical articulator as mechanical articulators do not represent effect of resilience of soft tissues and time dependent muscle guided movement is not possible.

Clinical Considerations

In fabricating a prosthetic rehabilitation, whether it consists of just a single crown or a complete-mouth reconstruction, one of the main aims of the clinician is to simplify the procedures and reduce the time necessary to integrate it into the mouth of the patient. In extensive rehabilitations or in cases involving the anterior teeth, models of provisionals are cross mounted on articulator. It allows the technician to visualize the space available on the occlusal and palatal aspects not just statically, but, more importantly, dynamically as well, since the provisional restorations have been functioning and (should) have been successfully integrated in the mouth.

In cases where the teeth of only one arch are involved in the rehabilitation, it is very important to pay attention to how the impression and cast of the opposing arch are made. Regardless of the impression material used and the laboratory material in which it is poured, it is a delusion to think that the resulting model is an exact duplicate of the patient's mouth.[12] There will be differences between the stone (or resin) model and the patient's arch. This results in an intercuspation of the two models that does not replicate that found intraorally. To compensate for this problem is to precisely record on the lab prescription form the occlusal contacts found in the mouth with an 8- to 15-µm shimstock articulating paper after mounting. Technician can accordingly perform occlusal adjustments of the models before beginning the fabrication of prosthesis to identify same occlusal points as found in mouth hence, can save the time in adjusting occlusion and in regaining the proper vertical dimension.

Summary

Articulator is an inevitable part of Prosthodontics in particular and all other dental fields in general. There are many types of articulators available with wide range of adjustments. Despite being the most accurate, the fully adjustable articulators are not feasible for every case because of their complex nature. Similarly, use of small non adjustable articulator is not recommended for complex cases. So, choice of articulator must be made very precisely depending on the requirement. Also, it must be recognized that the person operating the instrument is more important than the instrument. If dentists understand articulators and their deficiencies, they can compensate for their inherent inadequacies.

References

1. Sumiya Hobo,Herbert T. Shillingburg, Lowell D. Whitsett: Articulator selection for restorative dentistry: J Prosthet Dent: 36:35-43: 1976

2. Shillingburg Herbert T., Sumiya Hobo, Jacobi R. and Lowell D. Whitsett: Fundamentals of Fixed Prosthodontics 3rd ed. London: Quintessence Publishing Co. 1997.

3. Dr. Ammar, A. Alsa'ady: Using of articulators in the construction Of crown and bridges work in Baghdad:(A survey study): MDJ: 5 :2 2008

4. Jaffrey P. Okeson: Management of Temporomandibular Disorders and Occlusion, 6th edition: Chap 18

5. Stephen F. Rosenstiel, Martin F. Land, and Junhei Fujimoto: Contemporary Fixed Prosthodontics. 2nd ed. St. Louis, Missouri Mosby 1995.

6. Clyde H. Schuyler: The function and importance of incisal guidance in oral rehabilitation: J Prosthet Dent: 86:3: 2001

7. Peter E. Dawson: Functional Occlusion from TMJ to smile design: St. Louis, Missouri Mosby 2007

8. Weinberg, L.A.: An Evaluation of Basic Articulators and Their Concepts. Part I. Basic Concepts, J. Prosthet. Dent. 13: 622-644, 1963

9. Hodge, L.C., and Mahan, P.E.: A Study of Mandibular Movement From Centric Occlusion to Maximum Intercuspation, J. Prosthet. Dent. 18: 19-30, 1967

10. Verma AK et al: Articulators- A review article: Int J App Res: 1:1: 06-08: 2014

11. Gugwad.R.S et al: Virtual articulators in prosthodontics: Int J Dent Clin: 2011:3(4):39-41

12. Stefano Gracis: Clinical Considerations and Rationale for the Use of Simplified Instrumentation in Occlusal Rehabilitation. Part 2: Setting of the Articulator and Occlusal Optimization: Int J Periodontics Restorative Dent 2003;23:2

FINITE ELEMENT METHOD

Abstract

FEM is an engineering resource used to calculate stress and deformations in complex structures, and it has been widely used in biomedical research. It is a modern tool for numerical stress analysis, which has the advantage of being applicable to solids of irregular geometry that contain heterogeneous material properties. The finite element analysis provides the orthodontist with quantitative data that can extend the understanding of physiologic reactions that occur within the dento-alveolar complex.

Pooja Girsa*, Sridhar Kannan, Nitin Arora***, Ashish Kumar Singh****, Abhita Malhotra*****

* PG Student, Dept. of Orthodontics, Manav Rachna Dental College, Faridabad
** Head of Department, Dept of Orthodontics, Manav Rachna Dental College, Faridabad
*** Professor, Dept. of Orthodontics, Manav Rachna Dental College, Faridabad
**** Reader, Dept. of Orthodontics, Manav Rachna Dental College, Faridabad
***** Senior Lecturer, Dept. of Orthodontics, Manav Rachna Dental College, Faridabad

Introduction

In the last decade, the application of well proven engineering method the finite element method or the finite element analysis (FEA) has revolutionized in the field of dentistry especially orthodontics.

The FEM is an engineering resource used to calculate stress and deformations in complex structures, and it has been widely applied in biomedical research.[1] It is a modern tool for numerical stress analysis, which has the advantage of being applicable to solids of irregular geometry that contain heterogeneous material properties. This method is useful for interpreting the mechanical aspects of biomaterials and human structures which can be hardly measured in vivo.

The finite element analysis provides the orthodontist with quantitative data that can extend the understanding of physiologic reactions that occur within the dento-alveolar complex. From the analysis of stress and strain, to revealing the concepts of center of resistance and moment to force ratios, to determining the effects of mini-implants on bone are studied using FEM.

Methodology in finite element method

The object to be studied is graphically simulated in a computer in the form of a mesh, which defines the geometry of the body being studied. This mesh is divided by a process called discretization, into a number of sub units termed elements. These are connected at a finite number of points called nodes. The results of FEM will be based upon the nature of the modeling systems and for that reason, the procedure for modeling is most important.[2]

Basic steps involved in carrying out FEA are:-

1. **Pre-processing:**

Construction of geometric model

The purpose of the geometric modeling phase is to represent geometry in terms of points, lines, areas and volume. Complicated or smooth objects can be represented by geometrically simple pieces (Elements).It can be achieved by:-

1) 3D – CT scanner: Usually done for modeling complex structures or living tissues.
For example : craniofacial skeleton, maxilla or mandible

2) 3D – Laser scanner: Usually done for modeling inanimate objects.
For example : modeling of brackets

A. Conversion of geometric model into finite element model:

Discretization is the process of dividing problem into several small elements, connected with nodes. All elements and nodes must be numbered so that a setup of matrix connectivity is established. The elements could be one, two or three-dimensional and in various shapes. The joining of elements at the nodes and eliminating duplicate nodes is termed as 'Meshing'.

B. Assembly/Material property data representation:

Equations are developed for each element in the FEM mesh and assembled into a set of global equations that model the properties of the entire system. Minimum material properties required are poisons ratio and young's modulus.

	Young's Modulus (GPa)	Density (gm/cm^3)	Poisson's ratio
Enamel	77.90	3.0	0.33
Dentin	16.6	2.2	0.31
Pulp	0.00689	1.0	0.45
Periodontal ligament	0.05	1.1	0.45
Alveolar Bone	3.50	1.4	0.33
Cortical bone	10.00	1.4	0.26
Cancellous bone	0.50	1.4	0.38

Table 1: Material properties used in FE model for Huang[17, 18]

C. Defining the boundary conditions:

Boundary conditions means that suppose an element is constructed on the computer and a force is applied to it, it will act like a free-floating rigid body and will undergo translatory or rotatory motion or a combination of the two without experiencing deformation. To study its deformation, some degrees of freedom must be restricted(movement of the node in each direction x, y, and z) for some of the nodes. Such constraints are termed boundary conditions.

D. Loading configuration:

Application of force at various points of geometry and its configuration.

2. Processing:

Solve the system of linear algebraic equation. The stresses are determined from the strains by Hooke's law. Strains are derived from the displacement functions within the element Combined with Hooke's law.

3. Post-Processing:

The output of FEM is in numerical form. It usually consists of nodal values of the field variables and its derivatives. The output is in form of color-coded maps. The quantitative analysis is determined by interpreting these maps.

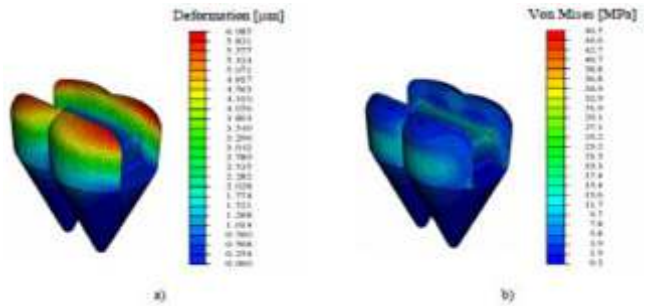

Review of literature

In the past, the force induced orthodontic tooth-movement have been studied using animal experimental methods. But nowadays due to ethical considerations these animal studies are forbidden. So, FEM studies are preferred as an alternative to these experimental studies. FEM is a non-invasive, accurate method that provides quantitative and detailed data regarding the physiological responses occurring in tissues, such as the periodontal ligament and the alveolar bone.

The history of Finite Element Analysis (FEA) dates back to 1943 when R. Courant first developed this technique. He utilized the Ritz method of numerical analysis and minimization of variation calculus to obtain approximate solutions to vibration systems. Later in 1956, Turner MJ et al. published a paper thereby establishing broader definition of numerical analysis. The paper centered on the "stiffness and deflection of complex structures".[4] It was introduced in implant dentistry in 1976 by Weinstein et al.

The FEM method was introduced in dental biomechanical research in 1973 by Farah et al. Since then, it has been used in dentistry to study biomaterials, tooth structure , biomechanics, dental implants, dental prosthesis and root canals.

Several studies have investigated the action of orthodontic forces on the craniofacial complex using the FEM. Mc Guinness et al applied the FEM to assess the distribution of orthodontic forces released by the Edgewise appliance.[5]The authors observed that stress concentration was higher at the cervical margin of the periodontal ligament and on the tooth apex. Kojima and Fukui sought to investigate possible orthodontic movements for anchorage teeth with the

application of a passive BTP.[6] The FEM results indicated that passive BTP presented almost no effect on anchorage maintenance due to the occurrence of mesial movement of molars when a mesial force was applied. Tominaga et al[7] proposed to analyze the en masse retraction in sliding mechanics.

Discussion

Over the years this method has undergone refinement and the results obtained have become more precise. Using finite element analysis, the orthodontic force applied can be simulated and the results can be shown on a three dimensional model that can be fabricated using a 3D scan software. Nowadays a number of FEM commercial software are available: ANSYS, ABAQUS,NISA,WECAN,NASTRAN-PATRAN ,HYPERMESH ,etc. Earlier CT sacns were used to scan the models.

Middleton et al. stated that the data obtained from this analysis is more accurate than any of the other experimental methods currently in use. It also allows for complete control over the variables in use while studying a homologous sample.[8]

The more structures are modeled, the more accurate are the results; however, it makes the model more difficult to be obtained and the analysis of the results more complex. Therefore, simpler models should be applied in order to obtain the same quantitative results. Modeling should be carefully assessed so as to simplify the model according to its actual needs and without compromising the results.

Drawback of FEM is the roots, periodontal ligament and teeth are represented in idealized geometric forms and physical properties are assumed to be homogenous, isotropic and linear.

Conclusion

The Finite Element Method (FEM) proves to be an important instrument in orthodontic research, such as: stress distribution areas in the periodontal ligament and alveolar bone during tooth movements, direction of the tooth displacement, the ideal position of orthodontic appliances during a specific mechanics, areas most likely to present root resorption. This method, however, requires knowledge in Computer Engineering, as it is run on very specific software.

References

1. Sameshima GT, Melnick M. Finite element-based cephalometric analysis. Angle Orthod. 1994;64(5):343-50.

2. Basic principles of finite element method and its application in orthodontics; Prasad Konda and Tarannum S A. / JPBMS, 2012, 16 (11)

3. Kazuo Tanne, Mamoru Sakuda, Charles J. Burstone.Three dimensional finite analyses for stress distribution in the periodontal tissue by orthodontic forces. Am J OrthodDentofacial Orthop1987; Volume 92(6):499-505.

4. M.J. Turner, R.W. Clough, H.C. MactinandL.J. Topp. Stiffness and defection analysis of complex structure. J. aeronaut science1956; 23:805-823.

5. McGuinness N, Wilson AN, Jones M, Middleton J, Robertson NR.Stresses induced by edgewise appliances in the periodontal ligament-afinite element study. Angle Orthod. 1992;62(1):15-22

6. Kojima Y, Fukui H. Effects of transpalatal arch on molar movement produced by mesial force: a finite element simulation. Am J Orthod Dento facial Orthop. 2008;134(3):335.

7. Tominaga JY, Tanaka M, Koga Y, Gonzales C, Kobayashi M, Yoshida N. Optimal loading conditions for controlled movement of anterior teeth in sliding mechanics. Angle Orthod. 2009;79(6):1102-10.

8. Middleton J, Jones M, Wilson A. The role of the periodontal ligament in bone modeling: the initial development of a time- dependent finite element model. Am J Orthod Dentofacial Orthop. 1996;109(2):155-62.

NEWER TRENDS IN HYPERTENSION

Abstract

HYPERTENSION is most common problem for which patients visit physicians. Improved control of hypertension has contributed to reduction of mortality and morbidity of disease. Few recent changes in management of hypertension are introduced i.e advances in management of hypertension have been introduced regarding systolic blood pressure and nutrition.

Nutrition plays an effective role in such patients, like. salt restriction, calcium supplementation, DASH DIET , potassium and magnesium supplementation etc. help to reduce blood pressure in such cases.

This article helps in reviewing recent trends in management of hypertension i.e management by combination of medicines and life style modification with nutrition recommendations for better control of disease.

Dr. Jyoti kiran Kohli*, Dr. Anupama V Betigeri, Dr. Vithalkumar M Betigeri*****

* Professor & Head of Department of Anatomy, Manav Rachna Dental College, Faridabad
** Reader, Department of Physiology, Manav Rachna Dental College, Faridabad
*** Professor, Department of CTVS, GB Pant Hospital, New Delhi

Introduction

HYPERTENSION is most common problem for which patients visit physicians .more than half of all persons older than 65 years have hypertension often isolated. Improved control of hypertension has contributed to reduction of nearly 60% in stroke related deaths and 53% in death from ischemic heart disease since 1972.(1)

Even in united states only 70% of hypertensive patients are aware of their condition only 59% are receiving treatment and only 34% have achieved adequate control. Although recommendations to identify and treat hypertension are universal but few recent changes in management of hypertension are introduced i.e advances in management of hypertension have been introduced regarding systolic blood pressure and nutrition.

Review

Although physicians have emphasized management of diastolic and systolic blood pressure and pulse pressure which correlate more strongly with cardiovascular disease risk than does diastolic blood pressure and treatment of isolated systolic blood pressure reduces vascular complications.(1)

As seen that most of hypertensive patients have isolated elevation of systolic blood pressure.(2,3) diastolic pressure is still important, however it is a clinical marker for hypertensive emergency (i.e when diastolic pressure is > 120 mm of Hg), not associated with new /progressive and end organ damage(4,5).

Table

Systolic/diastolic pressures (mm of HG)	JNC7	2017 ACC/AHA
<120 AND <80	NORMAL BP	NORMAL BP
120-129 AND < 80	PREHYPERTENSION	ELEVATED BP
130-139 OR 80-89	PREHYPERTENSION	STAGE 1 HYPERTENSION
140-159 OR 90-99	STAGE 1 HYPERTENSION	STAGE 2 HYPERTENSION
>OR =160 OR > OR = 100	STAGE 2 HYPERTENSION	STAGE 2 HYPERTENSION.

BLOOD PRESSURE CLASSIFICATION BY JNC 7 AND 2017 ACC/AHA HYPERTENSION GUIDELINES.(10)

Management

BLOOD PRESSURE STAGES	TREATMENT STRATEGIES
Prehypertension	Lifestyle modification ,drug therapy in patients with diabeties or chronic kidney disease.
Stage 1	Thiazides like diuretics , ccBs, ACE inhibiter .
Stage 2	two first line drugs -- combination therapy , once a day. Two -drug combination for most patients

Stages of hypertension and treatment stratagies as recommended by JNC -7.(6)

Role of nutrition

Nutrition plays an effective role in such patients.

- salt restriction (6)

- calcium supplementation
- potassium and magnesium supplementation help to reduce blood pressure in such cases.

DASH diet (dietary approaches to stop hypertension) i.e diet which is high in fruits, vegetables, nuts, whole grains, fish, poultry and low fat dairy products. Diet high in calcium, potassium, magnesium, low in red meat, sugar, fat and cholesterol is recommended.

Patients with hypertension who follow DASH diet in addition to reducing sodium intake (evidence level C , expert guidelines). (1)

Thus current epidemic of obesity in united states i.e BMI > or = 27, truncal obesity is associated with elevated blood pressure, which can be reduced by losing as little as 4.5 kg of body weight (7,8).

EUROPEAN SOCIETY OF HYPERTENSION (ESH) 2018, HYPERTENSION GUIDELINES

CATAGORY	SYSTOLIC (MM OF Hg)	DIASTOLIC(MM OF Hg)
optimal	<120	<80
Normal	120-129	80-84
High N	130-139	85-89
GRADE 1	140-159	90-99
GRADE 2	160-179	100-109
GRADE 3	>Or =180	>or=110
Isolated systolic Hypertension	>Or = 140	<90

TABLE : newer range of hypertension according to ESH

OFFICE BP TARGETS - office blood pressure be measured repeatedly and if raised should be lowered to **140/90 mm of Hg** in all patients but should be < than 130/80 mm of Hg. In most patients.

If patient is >65yrs, systolic BP goal is 130-140 mm of Hg.(9)

Treatment -1. Combination treatment - as initial therapy.

2. if BP is not controlled by two drug combination then it can be increased to three drugs. i.e **RAS** (rennin angiotensin system) **+ calcium channel blockers** (ccB) **+ thiazides** are preffered one.(11,12)

Newer concepts -

a) Lower BP thresholds and treatment targets for older patients with emphasis on biological rather than chronological age.

b) A single pill treatment strategy for hypertensive with preferred use SPC therapy.

c) Target BP ranges for treated patients to better identify the comorbidities according to patient age and reach lower safety boundaries.

d) In general population of adults 60yrs or older , pharmacologic treatment should be initiated when the systolic pressure is 150 mmhg or higher, or when the diastolic pressure is 90mm of hg or higher treatment does not need to be adjusted if it results in a systolic pressure lower than 140 mm of hg, as long as it is not associated with adverse effects on health or quality of life.

e) While in general population younger than 60 years, pharmacologic treatment should be initiated when the systolic pressure is 140mm of hg or higher, or when the diastolic pressure is 90mm of hg or higher.

In addition according to newer guidelines –

f) -daily dose of almonds, dark chocolate improves lipid profile.

g) -intense exercise lead to 65% lower death rate in older women.

h) -smoking even one cigertte a day, increases cardiovascular risk.

i) -exercise may reverse negative cardiac effects of sedentary life.(6,10)

Bibliography

1. Mickel K, Magill M.D, Karen Gunning, New developments in the management of hypertension. Am Fam Physcian, 2003 sept 1; 68(5) : 853-858.

2. Reisin E,Jack AV (may 2009). Obesity and hypertension : mechanisms, cardio-renal consequences and therapeutic approaches. The medical clinics of north america.93(3): 733-51.doi:10.1016/j.mcna.2009.02.010.PMID 19427502.retrieved 2009-06-20.

3. Gaddam Kk, verma A,Thompson M et al (may 2009). Hypertension and cardiac failure in its various forms. The medical clinics of North America .93(3): 665-80.doi:10.1016/j.mcna.2009.02.005.PMID 19427496.Retrieved 2009-06-20.

4. B.S.Jandhyala .Hypertension : Physiological Basis and Treatment. Journal of pharmaceutical sciences ,vol 74(7) ,july 1985.797.

5. AGABITI-Rosei E (September 2008).From macro – to – microcirculation : benefits in hypertension and diabeties. Journal of Hypertension supplement. 26 (3) : s15-9.Doi : 10.1097/01.hjh.0000334602.71005.52.PMID 19363848.

6. Dresser G K, Feldmen RD, New trends in hypertension management : of salt , going solo and single pill combos. Current opinion cardiology ,2010 jul ; 25(4) : 342-9 . doi : 10.1097/HCO.obo13e32833a6e09.

7. Clinical guidelines on identification ,evaluation and treatment of overweight and obesity in adults: the evidence report, Md; National institutes of health, national Heart, Lung, and blood institute.1998.NIH Publication no. 98-4083.

8. Zemel MB. Calcium modulation of Hypertension and obesity : mechanisms and implications .J Am Coll nutr. 2001 2001; 20(5 suppl) : 428S-35S.

9. Wheton PK, Carey RM,Aronow WS ,et al.2017. Guideline for prevention, detection, evaluation and management of high blood pressure in Adults : A report of American college of cardiology / American heart association task force on clinical practice guidelines.J AM Coll CArdiol 2017; Nov 13 : (Epub ahead of print)

10. HERMANSEN k.Diet, blood pressure and hypertension.Br J Nutr.2000;83(suppl 1): s113-9

11. Werner CM Bohm (june 2008) .The therapeutic role of RAS blockade in chronic heart failure. Therapeutic Advances in cardiovascular disease. 2(3) : 167 -77.doi .10.1177/1753944708091777. Pmid 19124420. Retrieved 2009-06 -20. Woodwell DA. National ambulatory medical care survey :1996 summary, Adv data 1997 ; 295 : 1-25.

DENTISTS AND MUSCULOSKELETAL DISORDERS

Abstract

Dental professionals may experience pain in back, neck and shoulders due to strain involving the joints, fatigue and repetitive movements, hence prone for musculoskeletal disorders. The pain may increase gradually and frequently, which requires proper management with medication. Ergonomics along with regular exercise can help in improving the quality of life.

Dr. Reena Doomra*, Dr. Anjana Goyal**

* Reader, Department of Pharmacology, Manav Rachna Dental College, Faridabad
** Reader, Department of Biochemistry, Manav Rachna Dental College, Faridabad

Majority of the dentists experience pain in the neck, low back or upper limbs which are commonly vulnerable to musculoskeletal disorders.(1)Job-related musculo skeletal disorders (MSDs) usually happen over a period of time, resulting from repeated workload exposures. The World Health Organization defines musculoskeletal disorders as problems involving muscles, tendons, joints, intervertebral discs, peripheral nerves and vascular system. It is not an acute condition, but develops slowly due to body's inability to heal itself from the long term effects of repetitive motion, exposure to vibration and/ or mechanical stress.(2)

Dental professionals spend most of their work days in static, awkward positions. The dental procedures are frequently performed with the cervical spine rotated and flexed forward, leading to high static load in the neck region. The contributory factors can be repetitive movements which can result in neck pain, tension neck syndrome or cervical instability.(3)Cervical spondylosis may occur and the dentist may be complaining of intermittent neck and shoulder pain or stiffness, headache, arm pain or numbness.(4) Osteoarthritis of the cervical spine and cervical spondylosis occurs in patients who maintain a flexed head for long duration. The frequency ofneck pain and cervical spondylosis is high among dentists.(5)Low back pain is one of the most common musculoskeletal complain, in which there is stiffness in the lower spine and surrounding tissues.(6)

Sometimes, there may be painful trigger points in a muscle which is capable of sensitizing the peripheral and central nervous system, resulting in pain referral to distant sites.(7)Biomechanical factors play a role in the development of myofascial trigger points. Prolonged forward flexion of head and neck leads to instability in the cervical spine. The patients have pain and inflammation of the neck muscles due to overload and unstable neck postures.(5)

Early symptoms of MSDs include pain, swelling, tenderness, numbness and loss of strength. Others symptoms are excessive fatigue in the shoulders and neck, tingling, burning, or pain in arms, weak grip, cramping of hands, numbness in fingers and hands, clumsiness and dropping of objects, hypersensitivity in hands and fingers.(8) Trigger points impair active and passive range of motion (ROM). Fixed postures maintained for long periods of time or repetitive movements also produce muscle stress. Muscle overload can lead to release of neurotransmitters and cytokines, which cause peripheral nociceptors activation, leading to pain. Inpatients having tension neck syndrome (TNS), pain is frequently associated with rigidity and muscle spasm. Pain may radiate to the arms, shoulder and head. The risk factors include occupation or profession, inability to perform a task properly, minimum social support and some individual characteristics. (9)

Pain can be relieved by NSAIDs like diclofenac, topical analgesic anti-inflammatory ointments/ gels/ sprays, hot fomentation, giving rest to the affected area.

Thiocolchicoside acts on glycine and γ-aminobutyric acid (GABA) receptors leading to muscle relaxation with analgesic action. It has been shown to reduce myofascial trigger point pain when given topically. (10)

Long term management would be to adapt to a healthy lifestyle, exercises and proper nutritious diet. These problems can be avoided largely by increasing the awareness of adapting good postures used during the work, redesigning the work station to promote neutral positions, examining the impact of instrument use on upper extremity, and following healthy work practices to reduce the stress of dental work on the practitioner's body.(11)

Helpful tips for a good working posture:

Maintain an erect posture, use of an adjustable chair with lumbar, thoracic and arm support, working close to one's body, minimize excessive wrist movements, avoid excessive finger movements, alternate work positions between sitting, standing and side of the patient, adjust the height of the chair and the patient's chair to a comfortable level, consider horizontal patient positioning, position the adjustable light to avoid strain on the neck and maintain an optimum temperature at workplace.

Body strengthening exercises:

Stretching and strengthening the muscles that support the back and neck, and muscles in the hand, forearm and wrist, will help them remain strong and healthy. Taking short breaks during the day and periodic stretching will avoid muscle fatigue. Giving rest to the hands is frequently believed to be one of the most important factors in preventing aches and pain which are usually the initial alarming symptoms in the patient.

To relieve eyestrain caused by focusing intensely at one site for long periods, shift and focus the eyes at a distance for approximately 15-20 seconds. Exercises such as head rotation should be done to prevent neck stiffness. Shoulder shrugging can be used to stretch the shoulder muscles that may be stressed and strained from holding oral evacuator, instruments and repetitive movements. Shoulder exercises like pulling up the shoulders toward the ears, rolling them backward and then forward in a circular motion will prevent aches and pain and prevent MSDs. (12)

Ergonomics along with regular exercises, relaxation techniques like meditation, yoga along with proper diet helps dentists deal with professional stress,and avoid injury to the muscles and joints, thereby improving the quality of life.

References:

1. Bernacki EJ, Guidera JA, Schaefer JA, et al.: An ergonomics program designed to reduce the incidence of upper extremity work related musculoskeletal disorders. J Occup Environ Med, 1999, 41: 1032–1041.
2. Al-Otaibi T. Repetitive strain injury. Saudi Med J 2001; 22:398-402.
3. Bansal A, Bansal P, Kaur S, Malik A. Prevalence of neck disability among dental professionals in North India. J of Evolution of Med and Dent Sci. 2013; 45 (2); 8682-8.
4. Ramamurthy B, Tandon P. Textbook of Neurosurgery. 2nd edition. 775-777.
5. Dajpratham P, Ploypetch T, Kiattavorncharoen S, Boonsirisseth K. Prevalence and associated factors of musculoskeletal pain among the dental personnel in a dental school. J Med Assoc Thai. 2010 Jun; 93 (6): 714-21.
6. Bradley W. Neurology in clinical practice. 5thedn.441-445.
7. Simons DG, Travell JG, Simons LS. Myofascial pain and dysfunction: the trigger point manual, Vol 1. 2nd ed. Baltimore, MD: Williams & Wilkins; 1999.
8. Puriene A, Janulyte V, Musteikyte M, Bendinskaite R: General health of dentists Literature reviews. Stomatologija, Baltic Dental and Maxillofacial Journal, 2007;9(1):10-20.
9. Feng B, Liang Q, Wang Y, et al. Prevalence of work related musculoskeletal symptoms of neck and upper extremity among dentists in China. BMJ Open 2014; 4: e006451. Doi:10.1136/ bmjopen-2014-006451.
10. Kellgren JH. A preliminary account of referred pain arising from muscle. British Med J1938b; 1:325-327.
11. Jabbar TAA: Musculoskeletal disorders among dentist in Saudi Arabia. Pakistan Oral and Dental Journal, 2008;28(1):135-144.
12. Yamalik N: Musculoskeletal disorders (MSDs) and dental practice Part 2. Risk factors for dentistry, magnitude of the problem, prevention, and dental ergonomics.Int Dent J, 2007, 57: 45–54. [Medline]

TOOTH SUPPORTED OVERDENTURE : A CASE REPORT

Abstract

The concept of conventional tooth-retained overdentures is a simple and cost effective treatment. When few firm teeth still remain in a compromised dentition, preservation of these teeth for overdentures can improve retention and stability. This helps improve retention and stability of final prosthesis significantly. The concept of overdentures may not be the elixir, but it is a positive means for delaying the process of complete endentulism and helps in the preservation of bone.

Keywords: Overdenture, Prosthesis

Dr. Pallawi Minhas*, Dr. Pankaj Dhawan, Dr. Pankaj Madhukar***, Dr. Piyush Tandon****, Dr. Shivam Singh Tomar*****, Dr. Divyesh Mehta******, Dr. Mansi Nautiyal*******

* Post-Graduate Student, Department of Prosthodontics, Manav Rachna Dental College, Faridabad
** Prof. & Head, Department of Prosthodontics, Manav Rachna Dental College, Faridabad
*** Prof., Department of Prosthodontics, Manav Rachna Dental College, Faridabad
**** Prof., Department of Prosthodontics, Manav Rachna Dental College, Faridabad
***** Senior Lecturer, Department of Prosthodontics, Manav Rachna Dental College, Faridabad
****** Senior Lecturer, Department of Prosthodontics, Manav Rachna Dental College, Faridabad
******* Senior Lecturer, Department of Prosthodontics, Manav Rachna Dental College, Faridabad

Introduction

Retaining teeth for an overdenture is an old concept and a viable treatment modality.[1] According to DeVan golden statement "Perpetual preservation of what remains is more important than the meticulous replacement of what is missing" still rings true. Overdenture is one of the most practical measures used in preventive dentistry. Overdenture is a better option as compared to a removable complete denture prosthesis, which certainly has its drawbacks. A complete denture patient goes through a sequel of events like loss of discrete tooth proprioception, progressive loss of alveolar bone, transfer of all occlusal forces from the teeth to the oral mucosa and the most depressing sequel is the loss of patient's self-confidence. In addition to this overdentures offer many advantages as preservation of proprioception retardation of alveolar bone resorption, psychological advantage of preserving natural teeth and improved chewing efficiency as compared to conventional complete dentures[2,3,4].

According to GPT 8, "Overdenture is a removable partial or complete denture that covers and rests on one or more remaining natural teeth, roots, and/or dental implants; a dental prosthesis that covers and is partially supported by natural teeth, tooth roots, and/or dental implants." It is also called as overlay denture, overlay prosthesis and superimposed prosthesis.

The key to success of an overdenture is the selection of strategic roots or teeth for retention. Abutment teeth are prepared, to create adequate space for the overlying denture. The shortened crown improves the crown-to-root ratio, thereby decreasing the motility of the abutment teeth under an overdenture.[5]

The concept of preserving natural roots for better prosthodontic prognosis is very old. Ledger6 in 1856 described something similar to overdenture prosthesis. His restorations were referred to as 'plates covering flangs' at that time. In 1961 Atkinson[6] published an article with the same title. Overdentures received special attention and were popularized particularly between the period of 1970 and 1980.[7]

Overdenture is indicated in patients with few remaining retainable teeth in an arch. It is also preferred in patients with malrelated ridge cases; patients needing single denture; patients with unfavorable tongue positions, muscle attachments, and high palatal vault, which render the stability and retention of the prosthesis difficult.[8] Overdentures are contraindicated in patients with questionable oral prophylaxis, systemic complications, and inadequate interarch distance.

Case Report

A 55-year-old patient reported to the Department of Prosthodontics in Manav Rachna Dental College to get his missing teeth replaced. Radiographic and clinical examination revealed that patient was partially edentulous in maxillary and mandibular arches with presence of 11, 13, 21, 23, 27, 34, 37, 44 Fig. 1 & 2) with grade I mobile 11, 21 and 37. Medical history was non contributory. Periodontal health status of the remaining teeth was assessed. The remaining teeth should have at least one half of the root length embedded in alveolar bone without a pocket depth higher than 3 mm to allow a favourable crown-to-root ratio for an overdenture retained by short-copings. The patient gave history of loss of his missing teeth over a period of 15 years due to multiple caries and periodontal problems. After thorough diagnostic evaluation, treatment plan was formulated and discussed with patient. An overdenture for maxillary and mandibular ridge were planned with extraction of 11, 21, 37. Tooth 13, 23, 27, 33, 43 were root canal treated and tooth preparation was done and copings were placed(Fig. 3). Primary impressions (alginate) were then made followed by final impressions (green stick compound and Zinc oxide eugenol paste), (Fig. 4 A, B & C) and then jaw relation recorded using conventional techniques. Teeth arrangement done and trial done. After satisfactory trial, denture was fabricated. Final occlusal refining was then accomplished and the patient was educated on insertion and removal of the new dentures. (Fig. 5 A & B)

Fig. 1 showing intraoral examination of patient

Fig. 2 showing preoperative OPG of the patient

Fig. 3 with completed maxillary and mandibular crown preparation and short coping cemented

A

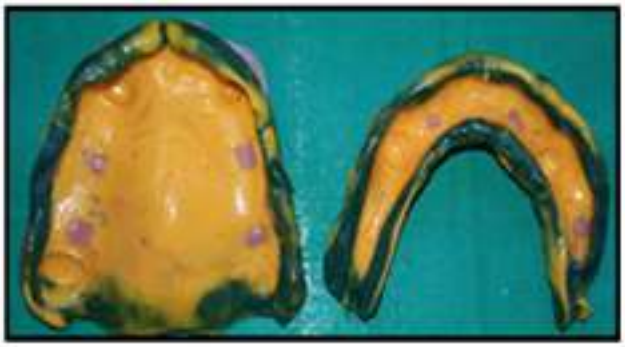

B

C

Fig. 4, Patients primary impressions(A),
Final impressions(B) & Master cast obtained(C)

A

B

Fig. 5 Final Denture insertion (A & B)

Discussion

Despite the enhancement of support and stability, maintenance of strategically located teeth offers several advantages for the patients from biological and functional aspects. An overdenture diminishes the ridge's bone resorption around the teeth and adjacent areas and also maintains dental proprioception. Even though the teeth are located inside the denture's basal area, maintenance of teeth leads to enhanced self-esteem and confidence in social life. From a psychological perspective, patient's own acceptance when wearing an overdenture is greater when compared to traditional complete dentures.[9] It is important to highlight that a correct mouth care regimen should be followed in patients with teeth/root supported overdentures, as treatment failures are attributed to poor oral hygiene and inadequate follow up care, leading to caries or periodontal disease.[10] Due to small height, the use of short-copings reduce the possibility of fracture of the overdenture base, when compared with higher coping, as telescopic crowns and attachments, as well the stress distribution in remaining teeth is lower in short-copings, especially in non-axial forces. Although a coping with higher height and attachments, may present greater stability and retention.[11] To preserve the health of overdenture abutment teeth, the patient was instructed to comply with an oral self care program that included the use of fluoridated toothpaste, remove plaque effectively and regular check-ups every six months.[12] Therefore, oral rehabilitation with root-supported overdentures is an effective treatment and may be indicated as a clinical alternative in patients with systemic disorders or economic reasons that could impair an implant-based rehabilitation.

Summary

The present case described a simple alternative to conventional complete dentures, utilizing short copings an aid to improve retention of the prosthesis. In addition to the superior patient acceptance, this method also avoids the radical removal of remaining teeth for the replacement of missing teeth, which is against the basic principles of Prosthodontics.

References

1. Tallgren A. Changes in adult face height due to aging, wear, loss of teeth and prosthetic treatment. Acta Odontol Scand 1957;15:24.

2. Crum RJ, Loiselle RJ. Oral perception and proprioception: a review of the literature and its significance to prosthodontics. J Prosthet Dent 1972;28:215–23.

3. Fiske J, Davis DM, Frances C, Gelbier S. The emotional effects of tooth loss in edentulous people. Br Dent J 1998;184:90–93.

4. Shah FK, Gebreel A, Elshokouki A, Habib AA, Porwal A. Comparison of immediate complete denture, tooth and implant-supported overdenture on vertical dimension and muscle activity. J Adv Prosthodont 2012;4:61-7.

5. Lovdal A, Schei O, Waerhaug J. Tooth mobility and alveolar bone resorption as a function of occlusal stress and oral hygiene. Acta Odontol Scand 1959;17:61-75.

6. Preiskel HW. Overdentures Made Easy-A guide to implant and root supported prostheses. London: Quintessence Publishing Company Ltd.: 1996.

7. Burns RD. The mandibular complete overdenture. Dent Clin N Am 2004;48:603–623.

8. Brewer AA, Morrow RM. Overdentures Made Easy. 2nd ed. St. Louis: The C. V. Mosby Co.; 1980.

9. Scotti R, Melilli D, Pizzo G. Overdenture supported by natural teeth: analysis of clinical advantages. Minerva Stomatol 2003;52:201-10.

10. Toolson LB, Smith D, Phillips C. A 2-year longitudinal study of overdenture patients. Part II: Assessment of the periodontal health of overdenture abutments. J Prosthet Dent 1982;47:4-11.

11. Dong J, Ikebe K, Gonda T, Nokubi T. Influence of abutment height on strain in a mandibular overdenture. J Oral Rehabil 2006;33:594-99.

12. Brewer AA, Morrow RM. Overdentures. 2. ed. St. Louis: Mo: Mosby; 1980: 347.

SUCCESSFUL ENDODONTIC MANAGEMENT OF THREE ROOTED MANDIBULAR 1ST MOLARS - A CASE SERIES

Abstract

Radix entomolaris (RE) is considered to be an Asiatic trait. However, its prevalence in Indian population is found to be lower than in other Asian races. Hence, its awareness and identification is pivotal to achieve success in endodontics. This article presents a review on clinical approach and a case series on the detection and endodontic management of RE in mandibular first molars. Radix entomolaris was detected by identifying the presence of a double or extra root outline in the preoperative radiograph, modifying the access opening and closely inspecting the pulp chamber and was endodontically treated following cleaning, shaping, and obturation of the canals. Achieving the endodontic success in the presence of an RE requires adequate knowledge about its existence, diagnosis, morphology, canal configuration, and clinical approach.

Dr. Pooja Agarwal*, Dr. Dax Abraham, Dr. Arundeep Singh***, Dr. Sucheta Jala****, Dr. Mohana Pratima******

* Post Graduate Student, Department of Conservative Dentistry, Manav Rachna Dental College, Faridabad
** Professor, Department of Conservative Dentistry, Manav Rachna Dental College, Faridabad
*** Principal, Manav Rachna Dental College, Faridabad
**** Senior Lecturar, Department of Conservative Dentistry, Manav Rachna Dental College, Faridabad

Knowledge of root canal anatomy is essential for successful root canal treatment. Post-treatment disease occurs because of persistent infection caused by unidentified or missed root canals, which in turn results in failure to remove all the pulp tissue and microorganisms from the root canal system (Bystro¨m et al. 1987, Sjo¨gren et al. 1997). Thus, an awareness and understanding of root canal anatomy is essential for improving the predictability of root canal treatment. Mandibular first molar teeth display several anatomical variations. (1)The major variant in this tooth type is the occurrence of a supernumerary (disto-lingual [DL]) root. This was first mentioned in the literature by Carabelli (1844) and was later termed radix entomolaris (RE) (Bolk 1915). (2)A mandibular first molar with three distal canals was first reported by Berthiaume (1983); however, the three distal canals ended in two apical foramina. Examples of mandibular first molars with three distal canals, all ending in separate apical foramina, have also been described (Stroneret al. 1984, Beatty & Interian 1985,Friedman et al 1986). (3)The prevalence of RE in mandibular first molars has been reported to be as low as 0.68% in Caucasians, 3% in African populations, and as high as 40% in Mongoloid populations .(4). Various studies have shown that populations of Asians have a prevalence of RE of 5.8% to more than 30% .The prevalence of RE is reported to differ significantly with races and ranges from 0-33.1%. The prevalence of RE is said to be highest among the population of Mongolian origin such as Chinese, Taiwanese, and Koreans which considered to be aneumorphic root morphology among them. Radix entomolaris is not very common in African, Eurasian, Caucasian and Indian population and it is said to be a dysmorphic root morphology in them.

The association between locating RE and other factors such as gender, right vs left side distribution and bilateral occurrence is said to be contradictory. Although few studies found male predilection for RE, no significant difference was found in the prevalence of RE according to gender. (5)(6) Similarly, no significant difference was found in the side occurrence, despite some studies reporting it to be more on the right side while other studies finding it more on the left side. The bilateral occurrence of RE is reported to vary from 37.14 to 67%. However, since some studies have reported only unilateral occurrence of RE, further studies are required to clarify this aspect.

The purpose of this article is to present a review on clinical approach for identification and endodontic management of RE and a case series on detection and root canal treatment of a mandibular first molar with RE.

Case Report 1:

An 18-year-old woman was referred to the Department of Conservative Dentistry and Endodontics, Manav Rachna Dental College with a chief complaint of tooth decay in her lower right back teeth for 2 months. History revealed intermittent pain in the same tooth during mastication. The patient's medical history was noncontributory. Clinical examination revealed a grossly decayed right mandibular first molar (tooth #30). Neither fistulae nor edema was observed in intraorally or extraorally. Tooth mobility was within physiological limits, and the gingival attachment apparatus was normal. The tooth was tender to vertical percussion. Thermal and electric pulp testing elicited a negative response. The preoperative radiograph showed widening of the periapical periodontal ligament space in relation to the mesial root apex. Also, the radiograph showed the presence of an extra distal root outline. Radiographs with mesial and distal angulations was taken to confirm the same. From the clinical and radiographic findings a diagnosis of pulpal necrosis with symptomatic chronic apical periodontitis with tooth #30 was made, and endodontic treatment was decided as the treatment of choice, for which the patient gave consent and a root canal treatment was initiated.

After caries excavation, the tooth was anesthetized by using 1.8 mL (30 mg) of 2% lidocaine containing 1:200,000 epinephrine (Xylocaine; AstraZeneca PharmaInd Ltd, Bangalore, India). A rubber dam was placed, and a conventional endodontic access opening was established using the Endo Access kit (Dentsply Maillefer, Ballaigues, Switzerland) . The pulp chamber floor was shown to have 4 canals connected by the developmental root fusion line. Coronal enlargement was done with a nickel-titanium (NiTi) ProTaper SX rotary file (Dentsply Maillefer, Ballaigues, Switzerland) to improve the straight-line access. Working length was determined with the help of an apex locator (Root ZX; Morita, Tokyo, Japan) and later confirmed by using a radiograph. Multiple working length radiographs were taken at different angulations to identify the second distal root. Cleaning and shaping were performed under rubber dam isolation by using ProTaper Next NiTi rotary instruments (Dentsply Maillefer), with a crown-down technique upto size X2. Irrigation was performed by using normal saline, 3% sodium hypochlorite solution, and 17% ethylenediaminetetraacetic acid. The access and instrumentation upto this point was carried out using a dental operating microscope. After completion of cleaning and shaping, the root canals were dried with absorbent points (Dentsply Maillefer). Calcium hydroxide (Calcicur; VOCO, Cuxhaven, Germany) was placed as an intracanal medicament with a lentulospiral (Dentsply Maillefer), and the access cavity was sealed with Cavit (3M ESPE Dental Products, St Paul, MN).

At the next appointment after 2 weeks, the patient was asymptomatic. Final rinsing of the canals was performed by using 2% chlorhexidinedigluconate with simultaneous ultrasonic agitation. The canals were dried with absorbent points (Dentsply Maillefer), and obturation was done by using cold lateral compaction of gutta-percha (Dentsply Maillefer) and AH Plus resin sealer (Dentsply Tulsa, Tulsa, OK). Access cavity was sealed with intermediate restorative material (IRM; Dentsply De Trey GmbH, Konstanz, Germany).

Figure 1:

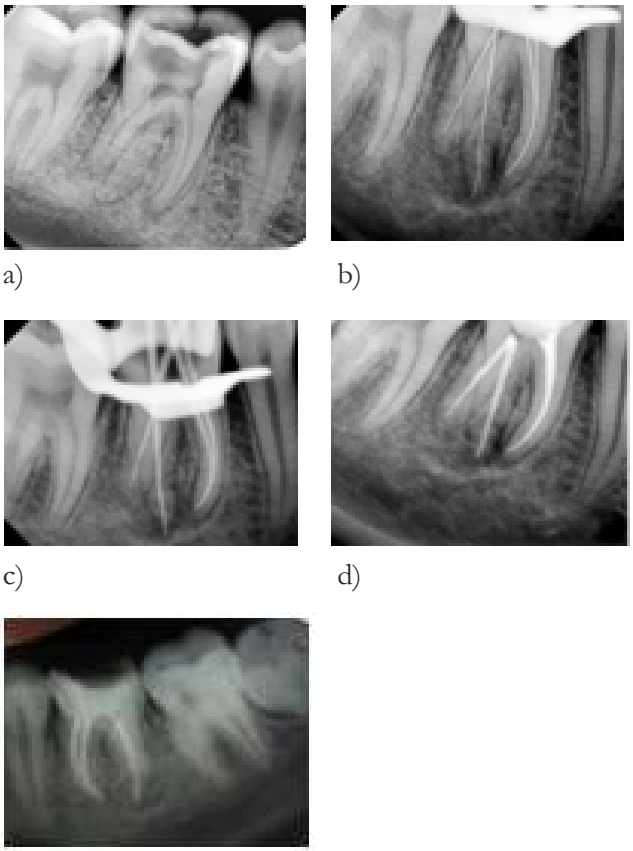

(a) Preoperative radiograph of mandibular right first molar revealed the extent of caries and the presence of an RE.
(b) working length determination
(c) Gutta-percha master cone fit was radiographically confirmed.

(d) Radiographic verification of obturation.
(e) 6 months follow up IOPA

Case 2:

A 30 year old male patient reported to the department of conservative dentistry and endodontics, Manav Rachna dental college with a chief complaint of decayed tooth in the lower left back tooth region since the past 2 months. The patient was asymptomatic. The patient's medical history was non-contributory. Clinical examination revealed a grossly decayed right mandibular first molar (tooth #19). There was no associated intraoral swelling with the tooth. There was no tenderness on palpation; tooth mobility was within physiological limits, and the gingival attachment apparatus was normal. Thermal and electric pulp testing elicited a negative response. The preoperative radiograph showed a deep occlusal carious lesion approaching the pulp. Also, the radiograph showed the presence of an extra distal root outline. Radiographs with mesial and distal angulations was taken to confirm the same. Endodontic treatment was decided as the treatment of choice, for which the patient gave consent and a root canal treatment was initiated.

After caries excavation, the tooth was anesthetized by using 1.8 mL (30 mg) of 2% lidocaine containing 1:200,000 epinephrine (Xylocaine; Astra Zeneca Pharma Ind Ltd, Bangalore, India). A rubber dam was placed, and a conventional endodontic access opening was established using the Endo Access kit (Dentsply Maillefer, Ballaigues, Switzerland) . The access opening was refined using an Endo Eze bur. The presence of four canal orifices was confirmed with DG-16 explorer.(Hu-Friedy, Chicago). Coronal enlargement was done with a nickel-titanium (NiTi) ProTaper SX rotary file (Dentsply Maillefer, Ballaigues, Switzerland) to improve the straight-line access. Working length was determined with the help of an apex locator (Root ZX; Morita, Tokyo, Japan) and later confirmed by using a radiograph. (Figure 2b) Multiple working length radiographs were taken at different angulations to identify the second distal root. Cleaning and shaping were performed under rubber dam isolation by using Neo Endo file system upto 25/0.06 (Orikam), with a crown-down technique. Irrigation was performed by using normal saline, 3% sodium hypochlorite solution, and 17% ethylenediaminetetraacetic acid. The access and instrumentation upto this point was carried out using a dental operating microscope. After completion of cleaning and shaping, the root canals were dried with absorbent points (Dentsply Maillefer). Calcium hydroxide (Calcicur; VOCO, Cuxhaven, Germany) was placed as an intracanal medicament with a lentulo spiral (Dentsply Maillefer), and the access cavity was sealed with Cavit (3M ESPE Dental Products, St Paul, MN).

At the next appointment after 10 days, the patient was asymptomatic. Final rinsing of the canals was performed by using 2% chlorhexidinedigluconate coupled with ultrasonic agitation.The canals were dried with absorbent points (Dentsply Maillefer), and master cone radiograph was taken (Figure 2 c). Obturation was done by using cold lateral compaction of gutta-percha (Neo Endo) and AH Plus resin sealer (Dentsply Tulsa, Tulsa, OK). Access cavity was sealed with intermediate restorative material (IRM; Dentsply De Trey GmbH, Konstanz, Germany).

Figure 2:

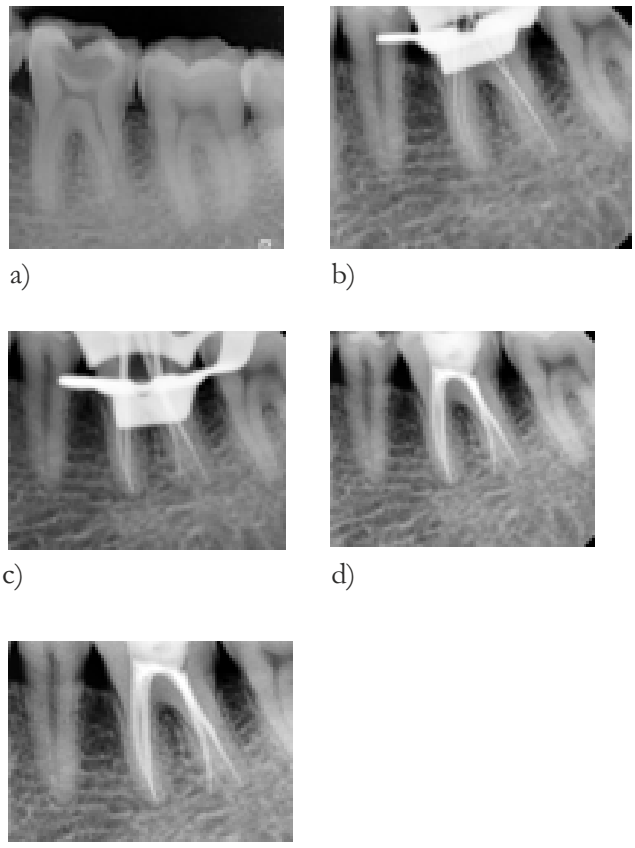

(a) Preoperative radiograph of mandibular left first molar revealed the extent of caries and the presence of an RE. (b)working length determination (c) Gutta-percha master cone fit was radiographically confirmed. (d) Radiographic verification of obturation. (e) 6 months follow up radiograph

Case 3 :

A 20 year old female patient reported to the department of Conservative Dentistry and Endodontics, Manav Rachna Dental College, with a chief complaint of pain in the lower right posterior tooth region since 3 months. Clinical examination revealed deep occlusal caries in mandibular right first molar (tooth 46). The tooth was very sensitive to percussion and apical palpation. On radiographic examination of tooth 46, apart from deep occlusal caries, periapical radiolucency was seen around the roots. Further, the presence of an additional distal root outline was noticed on the radiograph [Figure3a].

Following pulp testing, a diagnosis of pulp necrosis and acute alveolar abscess was made. The patient was suggested to undergo root canal treatment for which the patient gave consent and an emergency access opening was made to allow drainage. Following the initiation of root canal treatment, the close inspection of the pulp chamber revealed the presence of two mesial and two distal canal orifices. The access cavity was refined using an Endo Z bur. The presence of all the orifices were confirmed using an endodontic explorer [DG16, Hu-Friedy, Chicago]. Calcium hydroxide dressing was given in between visits. In the subsequent visit, canals were explored and negotiated using #08 and #10 size K-files [Dentsply Maillefer, Ballaigues, Switzerland]. The working length of the canals was determined electronically using an apex locator [J Morita] and confirmed radiographically. Canals were cleaned and shaped using rotary Ni-Ti files ProTaper Next (Dentsply-Maillefer] and crown-down technique. Canals were irrigated using 3% sodium hypochlorite solution and flushed with 17% EDTA solution to remove smear layer. Canal disinfection was carried out using calcium hydroxide [Calcicur, VOCO, Germany]. In this patient, the finding of a separate disto-lingual canal orifice and radiographic outline of the roots in the subsequent radiographs indicated the presence of an RE. In the follow up visits, when the patient was found asymptomatic, gutta-percha master cones [Pro Tapernext ,Dentsply Maillefer] were selected [Figure 3b]. Obturation was carried out with master cones and AH plus sealer [De Trey Dentsply, Konstanz, Germany]. (Figure 3c) The patient however was not available for a follow up radiograph.

Figure 3:

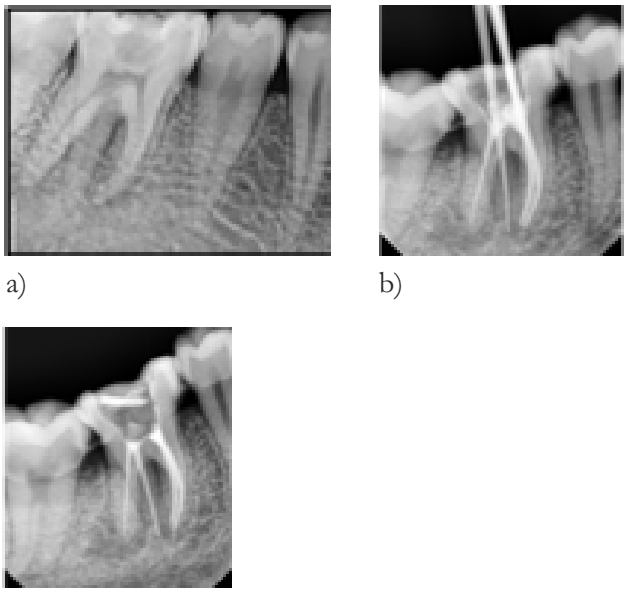

a) b)

c)

(a) Preoperative radiograph of mandibular left first molar revealed the extent of caries and the presence of an RE.
(b) Gutta-percha master cone fit was radiographically confirmed.
(c) Radiographic verification of obturation.

Discussion:

The success of root canal treatment depends majorly on accurate diagnosis, anatomy or morphology, canal configuration and clinical approach undertaken by the practitioner, followed by thorough mechanical and chemical debridement of the entire pulp cavity and complete obturation with an inert filling material. To achieve this goal, it is mandatory that the clinician has a complete knowledge and adequate preoperative assessment of the root canal morphology of each individual tooth being treated in the oral cavity .In the permanent dentition, the mandibular first molar has been considered to bear maximum biting force. It is one of the earliest erupting succedaneous teeth, as well as the one frequently suffering from pulpal disease and apical periodontitis (4). Also, mandibular first molars have been reported to have varied root and canal morphology, and many studies have been carried out to assess their anatomical characteristics.(4) It is now universally accepted that a major anatomical variant of the two-rooted mandibular first molar is a tooth with a lingually located supernumerary root. (4) This variant was first mentioned in the literature by Carabelli in 1844

and termed radix entomolaris (RE) (6); it refers to a distolingual extra root, as opposed to radix paramolaris when present buccally. It is characterized by the presence of an additional or extra third root, which is typically found disto-lingually. Radix entomolaris can be found in the first, second, and third mandibular molars, occurring the least frequently in the second molar.(6) This extra root is usually smaller than the disto-buccal (DB) root and is normally curved, instrumentation and filling of this additional root can pose challenges (Gu et al. 2011).(5)(7)

Endodontic success depends on. For RE, an accurate diagnosis can avoid complications like missed canal which is a common reason for endodontic failure. Clinically, apart from the awareness about the possible occurrence and the racial prevalence of RE, factors such as an extra cusp, (paramolar tubercle) prominent distolingual lobe, cervical convexity, complex external contour of the furcation can indicate the presence of an RE.

Radiographically, an unclear outline of the distal root or the root canal can point to the presence of an RE. However, this requires a thorough inspection of the preoperative radiograph. An angled radiograph (25-30°) can be extremely helpful in this regard and it is said that a mesially angled radiograph is better than a distally angled radiograph for RE detection. Another study suggested a 30° mesial horizontal beam to provide additional details of the root canal anatomical configuration of mandibular first molars in clinical and in vitro evaluations.(8) Nevertheless, according to Walker and Quackenbush, the accuracy of a correct diagnosis of 3-rooted mandibular molars is about 90%, even when using only panoramic radiographs.(3) Three-dimensional imaging techniques based on computed tomography (CT) and cone beam computed tomography (CBCT) are very useful aids in visualizing and understanding the true anatomic morphology of an RE in a noninvasive manner using less radiation. However, cost and access to them are the limiting factors. In the present case series, radiographs alone, including preoperative ones, clearly showed the presence of RE in all the cases signifying the importance of radiographs in the detection of RE and, from patient's point of view, prevented the need for expensive investigations such as CBCT. Thus thorough reading of the pre operative radiographs plays a very importance role prior to the initiation of treatment.

Carlsen and Alexandersen described 4 different types of RE, whereas DeMoor et al.(2) suggested a classification with 3 different types of RE: type I refers to a straight root, type II refers to an initially curved entrance that continues as a straight root, and type III refers to an initial curve in the coronal third of the root canal and a second curve beginning in the middle and continuing to the apical third. A classification given by Song et al (2010) described the various root morphologies of 3 rooted mandibular 1st molars. The DL root is located disto-lingually, with its coronal third completely or partially attached to the main distal root. Based on the original classification of De Moor et al. (2004), Song et al. (2010) also reported a variant of this classification and used the three types of morphologic features together with two newly defined types: (1) a small type, the length of which was shorter than half of the length of the DB root and (2) an even smaller conical type in which the root canal was absent.(9) In the present case series, radiographs alone, including preoperative ones, clearly showed the presence of RE in all the cases signifying the importance of radiographs in the detection of RE and avoided the need for expensive investigations such as CBCT. Changes in the conventional triangular access to obtain rectangular or trapezoidal outline form assists in locating the orifice of RE. Since canal orifices are equidistant from a line drawn in a mesio distal (MD) direction through the pulp chamber floor and lie on a line perpendicular to this MD line across the center of the floor of the pulp chamber, following the laws of symmetry, straight line access is essential and it helps in both detecting and locating an RE. Further, following the dentinal map on the floor of the pulp chamber may also act as a visual aid to indicate the position of an RE canal orifice.

Referenes :

1. Cleen M. Radix entomolaris. TandartsPraktijk. 2008;29(April 2016):2–3.

2. De Moor RJG, Deroose CAJG, Calberson FLG. The radix entomolaris in mandibular first molars: An endodontic challenge. Int Endod J. 2004;37(11):789–99.

3. Quackenbush LE. Mandibular molar with three distal root canals. Dent Traumatol. 1986;2(1):48–9.

4. Wang Q, Yu G, Zhou XD, Peters OA, Zheng QH, Huang DM. Evaluation of X-ray projection angulation for successful radix entomolaris diagnosis in mandibular first molars in vitro. J Endod [Internet]. 2011;37(8):1063–8. Available from:http://dx.doi.org/10.1016/j.joen.2011.05.017

5. Abella F, Patel S, Durán-Sindreu F, Mercadé M, Roig M. Mandibular first molars with disto-lingual roots: Review and clinical management. Int Endod J. 2012;45(11):963–78.

6. Vivekananda Pai AR, Colaco A, Jain R. Detection and endodontic management of radix entomolaris: Report of case series. Saudi Endod J [Internet]. 2014;4(2):77. Available from: http://www.saudiendodj.com/text.asp?2014/4/2/77/132723

7. Carlsen OLE, Alexandersen V. Radix entomolaris : identification and morphology. 1990;

8. Schilder H. Cleaning and Shaping the Root Canal. Dent Clin North Am. 1974;18(2):269–96.

9. Song JS, Choi HJ, Jung IY, Jung HS, Kim SO. The Prevalence and Morphologic Classification of Distolingual Roots in the Mandibular Molars in a Korean Population. J Endod [Internet]. 2010;36(4):653–7. Available from: http://dx.doi.org/10.1016/j.joen.2009.10.007

10. Krasner P, Rankow HJ. Anatomy of the pulp-chamber floor. J Endod. 2004;30(1):5–16.

3D OBTURATION : A CASE REPORT

Abstract

This case report describes an endodontic treatment of a mandibular second premolar with. A 19 year-old female patient reported pain in left mandibular second premolar. Clinical examination showed a large carious lesion with pulp exposure. Radiographs showed minimal periapical changes and slight widening of periodontal ligament space. Mandibular second premolars usually have one canal.. This case presents the diagnosis and clinical management of a mandibular second premolar with two distinct canals in the apical third of root, drawing particular attention to tactile examination of all the canal walls and obturating it with calamus 3D obturation system.

Dr. Arundep Singh*, Dr. Dax Abraham, Dr. Tushar Kohli***, Dr. Garima***, Dr. Anamika Sharma*****

* Professor & Principal, Manav Rachna Dental College, Faridabad
** Professor & Head of Department, Manav Rachna Dental College, Faridabad
*** Post Graduate, 2nd Year, Manav Rachna Dental College, Faridabad

Introduction

Sealing the root canal system is an important step in root canal treatment for a successful outcome [1]. Several techniques and materials have been introduced for a three-dimensional obturation with higher density and homogeneity [2]. Void-free filled canals carry a lower risk of apical periodontitis [3, 4]. Gutta-percha has long been used as a popular root filling material. The chemical and physical properties of guttapercha enable its application in several obturation techniques [5, 6]

Cold LC is a successful technique due to its simplicity, not requiring specific and expensive instruments and low cost [7]. Disadvantages of this technique include risk of void formation, inadequate adaptation of root filling material to the root canal walls and partial filling in certain hard-to-reach areas of the root canal system [8, 9]. Schilder [2] introduced WVC technique to improve the obturation quality in root canal irregularities. In this technique, he used heat-softened gutta-percha, and different sizes of pluggers to pack it.

The main advantages of thermo plasticized guttapercha techniques include better adaptation to root canal complexities, lower risk of void formation and creating a dense filling [10, 11]. CWC technique is a method of root canal filling with thermo plasticized guttapercha [12] using tapered pluggers to pack the heat-softened gutta-percha into the root canal system. In comparison to WVC technique, the CWC technique has the advantage of enhanced application and faster packing of guttapercha into the root canal system [13]. However, WVC technique may still be time consuming in many cases. Moreover, cleaning the remaining guttapercha at the orifice and coronal area is difficult.

Case Report

A 19 years old female patient with non contributory medical history reported to the OPD of the Department of Conservative Dentistry and Endodontics Manav Rachna Dental College Faridabad, with the chief complaint of the pain in right lower left back tooth region of jaw since 3 weeks, Patient gave history of pain in lower left back tooth region , pain is sharp, shooting , throbbing which aggrevates on chewing hot and sweat stuff. and relieved by taking analgesic.

Intraoral examination revealed discoloration and deep caries in relation to 34. 34was tender on percussion. Intraoral periapical radiograph revealed radiolucency involving dentin and pulp in relation to 34 (Figure 1). Pulp vitality test showed delayed response in relation to 34 suggestive of necrosis of pulp??.Root canal treatment for 35 was planned.

Figure 1: Preoperative Periapical Radiograph

Anaesthesia was obtained and an access cavity was prepared. In the floor of pulp chamber only single orifice was detected. Even with the exploration of the access cavity, no other orifices were found. Using K-file size number #15 (Dentsply, Maillefer, Switzerland) the working length was determined radiographically. This radiograph revealed a vague outline in the apical third which indicated canal splitting (Figure 2). Access was further widened and a number-15 file with severe precurve in the apical third was placed alongside of the first file and radiograph was taken again.

Figure 2 :working length determination

Then biomechanical preparation was carried out with 5.25% NaOCl as the irrigant and canal was prepared with protaper Next files up tol x2 master apical file. Calamus 3D system was used for obturation. The master cone, protaper Next up to x2 gutta-percha, was inserted to the full working length and apical tugback was checked. The master cone is typically cut back about 1.0 mm from the radiographic terminus (RT) so that its most apical end is just short of the "apical constriction." Three manual pluggers of diameters 0.7 mm, 0.9 mm, and 1.3 mm (Dentsply Tulsa Dental Specialties) were selected to compact the gutta-percha in coronal, middle, and apical thirds, respectively.

The Calamus Pack handpiece was activated to sear off the nonuseful portion of the master cone. During this procedure there is transfer of heat in the coronal 3-4 mm of gutta-percha. A large prefit plugger generates the first WOC (wave of compaction) and automatically compact warm gutta-percha vertically and laterally into the root canal system.

The pack handpiece was activated again; the EHP (electrically heated plugger) was plunged to 3-4 mm of the previously compacted material, deactivated, and then removed, along with a "bite" of gutta-percha. The medium prefit plugger carries a second wave of condensation and compact middle third of root canal system. This procedure was repeated for apical third of root canal. The downpack was now completed in main portion of the canal. The apical third obturation was now complete. The backfill phase was started by dispensing a longer 3 to 4 mm segment of warm gutta-percha into middle region of the canal. The working end of the medium size prefit plugger is stepped circumferentially around the preparation to clean the dentinal walls and flatten the dispensed material. Utilizing the plugger in this manner will promote successful hydraulics and generate "reverse" waves of condensation. The backfill phase was continued till the entire canal was filled (Figure 3).

Figure 3: 3D obturation wrt 34

Discussion

Hence, it is recommended that clinicians should consider a thorough assessment of radiographs. The crucial step in finding the split canal was tactile examination of main canal with a small, precurved K-

file tip [14]. After locating the canals, access was widened to facilitate root canal preparation. Root canal was prepared initially with hand files up to size number 20 and then continued with protaper Next files.

The calamus 3D obturation system was used for the obturation. The major benefits of this system are that Calamus Dual brings the flow and the pack together in one convenient, space-saving system. The downpack phase creates an effective apical plug and the backfill phase effectively seals lateral canals and furcal canals.

During the pack phase thermo-softened gutta-percha is moved into the narrowing cross-sectional diameters of the preparation and generates a piston effect on the entrapped sealer to fill canals laterally as well as create good apical corkage. During this heating and compaction cycle, the operator will tactilely feel the warm mass of gutta-percha beginning to stiffen as it cools. Importantly, using a plugger to press on warm gutta-percha during the cooling cycle has been shown to completely offset shrinkage [15].

The backfilling of canal is started by activation of flow handpiece. A short 2 to 3 mm segment of warm gutta-percha is dispensed into the most apical region of the empty canal. Small prefit pluggers are used to compact the warm gutta-percha in the middle third. This generates reverse wave of compaction. The backfill procedure is continued till the entire canal is filled.

Conclusion

Clinician should be aware of variations related to canal configuration and tactile examination is a key step in locating the extra/split canal. Three-dimensional obturation not only seals the apical third but also seals multiple portals of exit, that is, the accessory canals and furcal canals.

References

1. Grossman LI. Rationale of endodontic treatment.DentClin North Am. 1967. November; 483– 90.[PubMed]

2. Schilder H. Filling root canals in three dimensions. DentClin North Am. 1967. November; 723– 44.[PubMed]

3. Peciuliene V, Rimkuviene J, Maleniele R, Ivanauskaite D. Apical periodontitis in root filled teeth associated with the quality of root fillings. Stomatologija. 2006. April; 8 (4): 122– 6. [PubMed]

4. Keles A, Alcin H, Kamalak A, Versiani MA. Micro-CT evaluation of root filling quality in oval-shape canals. IntEndod J. 2014. February; 15 (2): 1– 8[PubMed]

5. Goodman A, Schilder H, Aldrich W. The thermo mechanical properties of gutta-percha. II. The history and molecular chemistry of gutta-percha. Oral Surg Oral Med Oral Pathol. 1974. June; 37 (6): 954– 61. [PubMed]

6. Schilder H, Goodman A, Aldrich W. The thermo mechanical properties of gutta-percha. Part V. Volume changes in bulk gutta-percha as a function of temperature and its relationship to molecular phase transformation. Oral Surg Oral Med Oral Pathol. 1985. March; 59 (3): 285– 96. [PubMed]

7. Peters CI, Sonntag D, Peters OA. Homogeneity of root canal fillings performed by undergraduate students with warm vertical and cold lateral techniques. Oral Surg Oral Med Oral Pathol Oral Radiol Endod. 2010. September; 110 (3): e41– 9.[PubMed]

8. Clinton K, Van Himel T. Comparison of a warm gutta-percha obturation technique and lateral condensation. J Endod. 2001. November; 27 (11): 692– 5. [PubMed]

9. Gencoglu N. Comparison of 6 different gutta-percha techniques (part II): Thermafil, JS Quick-Fill, Soft Core, Microseal, System B, and lateral condensation. Oral Surg Oral Med Oral Pathol Oral RadiolEndod. 2003. July; 96 (1): 91– 5. [PubMed]

10. Collins J, Walker MP, Kulild J, Lee C. A comparison of three gutta-percha obturation techniques to replicate canal irregularities. J Endod. 2006. August; 32 (8): 762– 5. [PubMed]

11. Emmanuel S, Shantaram K, Sushil KC, ManojL.An In-Vitro Evaluation and Comparison of Apical Sealing Ability of Three Different Obturation Technique - Lateral Condensation, Obtura II, and Thermafil. J Int Oral Health. 2013. April; 5 (2): 35– 43. [PMC free article] [PubMed]

12. Buchanan LS. The continuous wave of obturation technique: 'centered' condensation of warm guttapercha in 12 seconds. Dent Today. 1996. January; 15 (1): 60– 2, 64– 7. [PubMed]

13. Perry C, Kulild JC, Walker MP. Comparison of warm vertical compaction protocols to obturate artificially created defects in the apical one-third. J Endod. 2013. September; 39 (9): 1176– 8. [PubMed]

14. N. P. Gupta, R. Bansal, and M. Bansal, "Treatment of mandibular first premolar with type IV root canal: a case report," Indian Journal of Dental Sciences, vol. 2, no. 2, pp. 26–27, 2010. View at Google Scholar

15. B. Dadresanfar, Z. Khalilak, and S. Shahmirzadi, "Endodontic treatment of a maxillary first premolar with type IV buccal root canal: a case report," Iranian Endodontic Journal, vol. 4, no. 1, pp. 35–37, 2009.View at Google Scholar

GENERAL INFORMATION & GUIDELINES TO CONTRIBUTORS

The journal publishes original scientific papers, reviews, case reports and method presentation articles in the field of dentistry. Manuscripts submitted for publication must be original articles and must not have appeared in any other publication. The publisher reserves the right to edit manuscripts for length and to ensure conciseness, clarity and stylistic consistency, subject to author's final approval.

Ethical Guidelines

Experimentation involving human subjects will be published only if such research has been conducted in full accordance with the ethical principles.

Article Preparation

Original research

Should describe significant and original experimental observations and provide sufficient detail so that observations can be critically evaluated and. if necessary, repeated. Articles considered as original research include, randomized controlled trials, intervention studies, studies of screening and diagnostic test, outcome studies, case-control series, and surveys with high response rates. **Up to 2500 words excluding references and abstract.**

Short communication, short case presentations, and Method Presentation Articles

Short case presentation: Interesting cases that authors would like to share with the readers. Method Presentation Articles: must present significant improvements in clinical practice (a novel technique, technological breakthrough or practical approaches to clinical challenges). **Up to 1000 words excluding references and abstract and up to 10 references.**

Case Reports

New/interesting/very rare cases can be reported. Should have importance and significance. Repetition of well known and extensively published conditions will not be accepted. Include a thorough literature review and emphasize the clinical relevance. Up to 2000 words excluding references and abstract and up to 10 references.

Review articles

Must have broad general interest. Reviews should take a broad view of the field rather than merely summarizing the authors own previous work. Up to 3500 words excluding references and abstract.

Letter to the editor

Should be short, decisive observation. They should not be preliminary observations that need a later paper for validation. up to 400 words and 4 references.

email : dentallamina.mrdc@mrei.ac.in

Detail Guidelines are available online at www.mrdc.ac.in in the section JOURNAL on Homepage.

IMPORTANT NOTE : The journal considers Plagiarism as an offence that justifies retraction of article & issue of public statement against offenders. Kindly ensure the submitted work is original in content & any source of text of figures are not submitted without acknowledgment in references or legends with permission to reproduce rightly sought by the author from source.

CORRESPONDENCE ADDRESS :

EDITOR IN CHIEF
Prof. (Dr.) Shveta Sood, M.D.S.
Dental Lamina - Journal of Dental Sciences
Manav Rachna Dental College, Dept. of Paedodontics and Preventive Dentistry
Delhi - Surajkund Road, Aravali Hills, Faridabad, Haryana, INDIA
Phone : +91-9899000839
email : dentallamina.mrdc@mrei.ac.in

STATEMENT ABOUT THE
"DENTAL LAMINA" JOURNAL OF DENTAL SCIENCES
(Published twice a year in the months of January and July)

1. Place of publication	Manav Rachna Dental College
2. Periodicity of its publication	Bi-Annual
3. ISSN Number	2347-1859
4. Printer/Publisher's name	Mr. Rishabh Prabhakar
Nationality	Indian
Address	Plot No. 6, Industrial Area, NIT, Faridabad
5. Particulars of printing press	M/s. Prabhakar Press Plot No. 6, Industrial Area, NIT, Faridabad-121001, Haryana
6. Editors name	Prof. Shveta Sood
Nationality	Indian
Address	
7. Name & address of individuals who own the publication	M.R. Education Society [A Society Registered Under The Societies Registration Act 1960 - Regd. No. 2242/1987-88]

I, Dr. Shveta Sood, hereby declare that the particulars given above are true to the best of my knowledge and belief.

Sd/-

(Dr. Shveta Sood)

MANAV RACHNA
Vidyanatarksha

CAMPUS:
Sector - 43, Aravali Hills,
Delhi - Surajkund Road, Faridabad
Ph: +91-129-4268800 (30 Lines)

ADMINISTRATIVE HEADQUARTERS:
5E/1-A, G.F., Bungalow Plot,
N.I.T. Faridabad
Ph: +91-129-4198600 (30 Lines)